

FILAMENTARY KERATITIS - A REVIEW OF ETIOPATHOGENESIS AND MANAGEMENT

*Dr. Sarita Panda, *Dr. B.N.R. Subudhi, *Dr. R.C. Mohapatra, **Dr. Anita Panda

*Department of Ophthalmology, M.K.C.G. Medical College & Hospital, Berhampur (Gm.)

**R.P. Centre of Ophthalmic Sciences, AIIMS, New Delhi

INTRODUCTION :

Filamentary keratitis is relatively an uncommon disorder. It is characterized by the presence of fine filaments of epithelium and mucus that are attached to the cornea. Filaments are discrete, translucent, bulbous strands of mucus, intertwined with desquamated cells and cellular debris that hang from corneal surface and stain with Rose Bengal. Filaments vary in length from small stub to less than 2 mm. Filamentary keratitis tends to be recurrent in many inflammatory oedematous and degenerative states. It is associated with a number of corneal conditions which can be categorized into two groups i.e. local and systemic.

Local causes include kerato conjunctivitis sicca, superior limbic kerato conjunctivitis, aerosol keratitis, beta radiation, herpes simplex viral infection, recurrent erosions, thygeson's superficial punctate keratitis, chronic blepharospasm, following ocular surgery like cataract surgery and penetrating keratoplasty specially in rheumatoid arthritis and kerato conjunctivitis sicca patients, neurotrophic and neuroparalytic keratitis, prolonged occlusion of eyelids, retained foreign body beneath the upper lid, prolonged use of contact lens specially extended wear contact lens (EWSCL), dry eye syndrome or diseases, corneal oedema and drug toxicity like thimerosal.

Systemic causes include diabetes mellitus, psoriasis, ectodermal dysplasia, atopic dermatitis, osler-weber-render disease, primary Sjogren's syndrome secondary Sjogren's syndrome associated commonly with rheumatoid arthritis, EEC syndrome where ectrodactyly, epithelial dysplasia and clefting present.

PATHOGENESIS:

The exact cause of filamentary keratitis is not known but most of the theories described by many authors are centred on mucus and epithelial cells. as

these two compose the corneal filament, Gerald W. Zaidman et al. theorised that filaments formation are mainly due to three factors. (1) focal abnormalities of the superficial corneal epithelium. (2) scattered areas of damage to the basal epithelium, epithelial basement membrane or Bowman's layer. (3) excess mucus formation (Fig. 1). Basing on histopathological studies, they hypothesised that filaments were of epithelial origin and abnormality was found beneath the basal epithelial cells consisting of segmental damage to the epithelial basement membrane, with groups of inflammatory cells and fibroblast disrupting the interface between Bowman's layer and epithelial basement membrane. Hence, they believed the initial step in filament formation is damage to the basal epithelial cells, epithelial basement membrane or

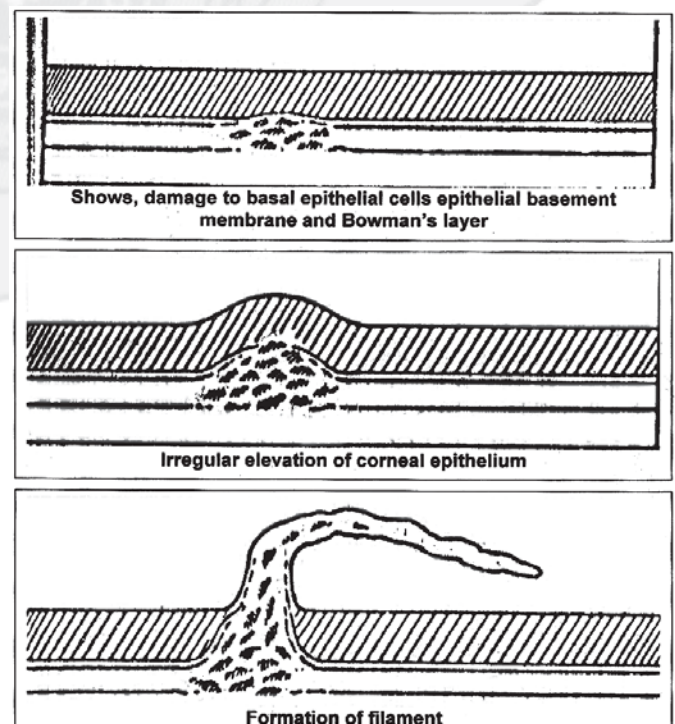


Fig. 1 : Diagram showing the etiopathogenesis of corneal filament

Bowman's layer: These lesions lead to focal areas of epithelial basement membrane detachment with time and under the shearing influence of the blinking eyelids, these affected areas of epithelium became elevated. Irregularity of corneal surface led to further eye inflammation and resultant production of large amounts of mucus and debris. The areas of epithelial elevation served as receptor sites for this material which led to eventual formation of corneal filaments. Some authors have described that there is close association between anticardiolipin antibodies IgM and IgG and filamentary keratitis.

Thiel et al postulated this was due to lesion at the level of the basal epithelial cells, possibly involving the epithelial basement membrane and Bowman's layer. Mandgal et al. hypothesized that there were areas of focal degeneration of the superficial epithelium. Wright suggested that filaments are primarily composed of mucus and epithelial cells attached. Secondly that filaments form when excess mucus and receptor sites (composed of localized patches of slightly elevated cells) are present.

According to David-W Lambert many factors have been implicated in the formation of corneal filaments, but by far the most common association is dryness. He postulated that in dry eye syndromes or diseases the pathogenesis of filament formation could be that when the cornea dries to a point that is incompatible with a healthy epithelial layer. Some surface cells becomes dessicated and shed. This creates a small pit on the corneal surface that is hydrophobic compared with the mucus coated normal surface. Lipid contaminated mucus becomes attached to these pits by hydrophobic bonding. Within a short time the surface epithelium grows down these mucus cores and a true filament is born in situ. On sectioning a filament one finds a periodic acid shift (PAS) positive central core (mucin) surrounded by epithelium.

According to Douglas Coster, three main factors contribute to corneal filament formation they are :

1. Abnormal epithelium acting as mucus receptors.
2. Abnormal tear movement
3. Abnormal shear relationship between upperlid and globe.

According to Robert R Jones et al. patients after cataract surgery who were suffering from rheumatoid

arthritis and kerato conjunctivitis sicca were more predisposed to develop filamentary keratitis. In another study done by Mark J. Mannis et al, they reported prevalence of filamentary keratitis in post keratoplasty patients.

Filamentary keratitis is also associated with prolonged use of contact lens specially extended wear contact lens (EWCL) and also sometimes associated with superior limbic kerato conjunctivitis in one third of cases. As Jules L. Baum postulated that filamentary keratitis is always related to prolonged eye lid closure which led to hypoxia of limbal cells of the superior limbus and this could be one of the factors leading to the development of superior limbic kerato conjunctivitis in predisposed patients having hypothyroid because the upperlid always covers the limbal cells underneath it.

In those patients who develop superior limbic kerato conjunctivitis (SLK) and consequently filamentary keratitis after soft contact lens wear (SCL) for long time. Exposure to thiomersol has been implicated as an etiologic agent. The hypoxic insult in SCL-SLK derives from coverage of the superior limbal stem cells by both upper eyelid and SCL and hence leads to filamentary keratitis. Thus SCL-SLK may arise because of stem cell exhaustion or result from combined effects of hypoxia and drug toxicity (e.g. thimersol). Long term use of other topical medications may also slowly deplete the stem cell population. Jules L. Baum also suggested because chronic hypoxia seems to play a significant role in prolonged eyelid closure in the development of stem cell exhaustion for those stem cells normally located under the eyelids and the term hypoxia induced stem cell epitheliopathy can be used.

MANAGEMENT :

Management of filamentary keratitis due to dry eye syndromes or diseases like kerato conjunctivitis sicca includes supplementation of tears by tear substitutes, preservation of existing tears, stimulation of tears, dispersal of mucin and usage of bandage contact lens.

Tear substitutes : They are marketed as drops, ointments and inserts. Polymeric composition of tear substitutes are methyl cellulose and derivatives, hydroxyethyl cellulose, polyvinyl alcohol, polyvinyl

alcohol and hydroxy cellulose, polyethylene oxide, polyvinylpyrrolidone and hydroxyethyl cellulose.

Preservation of existing tears: This is done by using Swimmer's goggles, clear food wrap shields. Silicone rubber shields, moist chamber spectacles, lid taping bandage contact lens and punctal occlusion. Punctal occlusion can be done by using solid gelatin rods, polyhydroxy ethylmethacrylate plugs, cyanoacrylate adhesives, silicone plugs electrocautery and laser. Electrocautery is performed in severe dry eye syndromes with schirmer less than 2 mm and is done permanently.

Stimulation of tears: Stimulation of lacrimal gland is done to produce more tears by medications like Bromhexine, Eledoisin and Physalaenin.

Dispersal of mucin: In mucin deficient dry eyes, where there is excess of mucus formation or mucus strands, Acetylcysteine 20% or 10% buffered to PH 8.4 along with sodium bicarbonate is used 3 to 4 times daily which helps breaking mucin into soluble components.

Bandage contact lens : In filamentary keratitis bandage contact lens (BCL) are treatment of choice. They are also helpful in exposure keratitis and mucus deficient dry eyes and in kerato conjunctivitis sicca. Concomitant use of BCL and artificial tears is advocated along with prophylactic antibiotic drop to prevent infection due to BCL. Artificial tears help to keep BCL moist. Thicker lenses with less water content is preferred to thinner lens with more water content as thicker lenses not tend to dehydrate. The lens is placed after the filaments are removed from the cornea, the patient experiences immediate symptomatic relief and the filaments usually do not reappear as long as the lens is in place.

CONCLUSION :

Prolonged eye lid closure has a definitive role to play in triggering hypoxic and dry eye states leading to filamentary keratitis and hence to be avoided. EWSCS usage is to be discouraged. As regards to preoperative evaluation of patients undergoing ocular surgery like cataract or penetrating keratoplasty other associated conditions like rheumatoid arthritis, kerato conjunctivitis sicca should specially be looked into, as they are predisposing factor for filamentary keratitis. As for the newer treatment schedules one should

consider Diclofenac sodium 0.1% as a better alternative than conventional treatment. In kerato conjunctivitis sicca with Sjogren's syndrome short term pulse therapy of non preserved methyl prednisolone may be beneficial as it takes care of the inflammatory component of the Sjogren's disease.

Reference :

1. Gerald W Zaidman, Ragnit Geeraets, Ralph R Paylor, Andrew P Ferry. The histopathology of filamentary keratitis. *Arch Ophthalmol* 1985; 103: 1178-1181.
2. Jules L Baum. Prolonged eyelid closure is a risk to the cornea 1997; 16: 602-11.
3. Douglas Coster *Cornea, Fundamentals of Clinical Ophthalmology, post surgical filamentary keratitis* 2002; 116.
4. David W Lamberts. *Thoft and smolin 3rd Edition. Clinical diseases of the tear film* 1987; 457-474.
5. *Parson's disease of eye, 18th Edition.*
6. Peter Marsh, Stephen, P Flugfelder. Topical nonpreserved methylprednisolone therapy for keratoconjunctivitis sicca in sjogren syndrome. *Ophthalmology* 1999; 106: 811-6.
7. Rahamim Avisar, Anat Robinson, Itiel Appel Yuval Yassur, Dov Weinberger. Diclofenac sodium, 0.1% (Voltaren Ophtha), versus sodium chloride 5% in the treatment of filamentary keratitis. *Cornea* 2000; 19: 145-7.
8. Aharon Grinbaum, Iftach Yassur, Isacc Avni, Tel Aviv Israel. The beneficial effect of Diclofenac sodium in the treatment of filamentary keratitis. *Arch Ophthalmol* 2001; 119: 926-7.
9. Robert R Jones, Leo J. Maguire corneal complications after cataract surgery in patients with rheumatoid arthritis. *Cornea* 1992; 11(2): 148-150.
10. Mark J Mannis, Karala Zadnik, Mark R Miller, Margaret Marque. Preoperative risk factors for surface disease after penetrating keratoplasty. *Cornea* 1997; 16 (1): 7-11.
11. Norn MS. Dessication of the pre corneal tear film. *Corneal wetting time. Acta Ophthalmol (Copenh)* 47; 865, 1969.
12. Gobbels M and Spitzans M. Influence of artificial tears on corneal epithelium in dry eye syndrome. *Graefes Arch clin Exp Ophthalmol* 227; 139: 1989.
13. Krishna N and Brown F. Polyvinyl alcohol as an ophthalmic vehicle. *Am J Ophthalmol* 57; 99: 1964.
14. Mishima S, Kubota Z and Farris RL. The tear flow dynamics in normal and in keratoconjunctivitis sicca cases. In MP solanes (ed.), *Proceedings of the 21st International Congress of Ophthalmology, Mexico March 8-11.*
15. Avisar R et al. Lysozyme content of tears in patients with sjogren's syndrome and rheumatoid arthritis. *Am J Ophthalmol* 87; 148: 1979.
16. Bardy GJ et al. Preservative free artificial tear preparations. Assessment of corneal epithelial toxic effects. *Arch Ophthalmol* 110; 528: 1992.
17. Collins HB and Grabsch BE. The effect of ophthalmic preservatives on the healing rate of the rabbit corneal epithelium after keratectomy. *Am J Optom Physiol Opt* 59; 215: 1982.
18. Freeman TM, Punctum Plug. Evaluation of a new treatment for dry eyes. *Trans Am Acad Ophthalmol Otolaryngol* 79: 874, 1975.