

Purtscher's-like retinopathy in acute alcoholic pancreatitis

Author names and affiliation

¹Dr. Praveen Subudhi FRCS(G)* ²Dr. Sanghamitra Kanungo MS# ³Dr. B.N.R Subudhi MS\$

*Consultant, Ruby Eye Hospital and Research Center, Govinda Vihar, Berhampur, Odisha, India

Senior Vitreo-retinal consultant, Kar Eye Hospital, Jayadev Vihar, Bhubaneswar

\$ Professor, M.K.C.G Medical College, Berhampur, Odisha, India

Financial Disclosure : None

Corresponding Author: Dr. Praveen Subudhi FRCS(G) MS DNB

Ruby Eye Hospital and Research center, Govinda Vihar, Berhampur, Ganjam, Odisha, India

Email id: subudhipraveen@gmail.com

Abstract:

A 28-year-old male presented with a sudden onset of visual loss in both eyes (OU). He was a known case of acute pancreatitis and hepatitis following alcohol abuse. The examination of the anterior segment of the eye





Figure 1(a) and (b); fundus photographs of the patient at the time of presentation showing typical Purtscher's flecken and presence of multiple cotton wool spots along superior vascular arcade, (c) and (d); showing reduction of ischemic zones consequent to steroid therapy.



revealed ill-sustained pupillary light reaction. The fundus showed typical Purtscher's flecken over posterior pole with multiple cotton wool spots and retinal superficial hemorrhages in OU. Fundus fluorescein angiogram showed abnormal hypo-fluorescence in the posterior pole of OU. Optical coherence tomography (OCT) showed abnormal retinal thickening with hyper-reflective areas in the inner neurosensory layers of OU. The patient

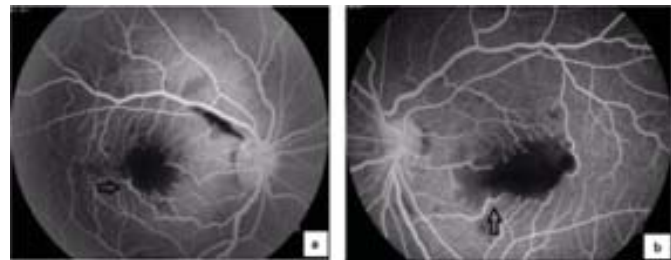


Figure 2 (a) and (b); Fundus fluorescein angiogram showing large ischemic areas over macula and margins of enlarged hypo fluorescent macula had pruning of small vessels suggestive of necrotic inflammation (shown in arrow mark)

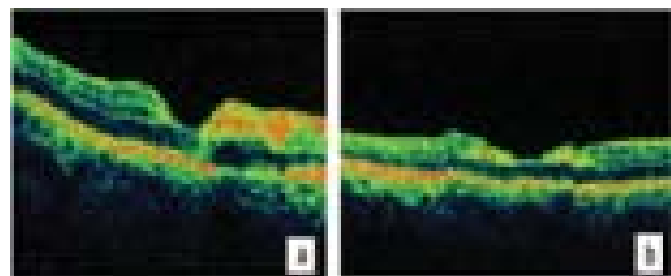


Figure 3: Optical Coherence Tomograph (OCT) showing abnormal hyper-reflective area along inner neurosensory layers, however outer hyper-reflective layer and inner segment - outer segment junction were within normal limits.

responded favorably to the high-dose corticosteroid therapy (1.5 mg/KBW) in a tapering dose. There was a mild reduction in ischemic areas in OU with corresponding improvement in the visual acuity. This case has been presented owing to its rarity. Nevertheless, the presence of symmetrical typical Purtscher's flecken and corticosteroids remain the mainstay treatment.

Keywords: Purtscher's retinopathy, Purtscher's flecken, macular ischemia, optical coherence tomography

Introduction:

Purtscher's and Purtscher's-like retinopathy are characterized by the sudden onset of unilateral or bilateral visual loss in cases of severe trauma to the head and thorax. [1] It is rarely reported worldwide owing to its low incidence and poor ophthalmic referral. Poor retinal perfusion and ischemic damage to the retina is the cause of visual loss. [6]

Case report:

A 28-year-old male presented to our hospital with complaints of bilateral sudden onset loss of vision. He was a known case of acute pancreatitis and hepatitis following alcohol abuse and was under medical management at a private clinic. His laboratory parameters showed raised serum trypsin (850 micrograms per liter) and alkaline phosphatase (ALP) (443 units per liter) levels. On ocular examination, his best corrected visual acuity was counting fingers at 2 feet in both eyes (OU). Anterior segment examination showed ill-sustained pupillary reactions in both eyes (OU). Posterior segment evaluation revealed clear optical media with typical Purtscher's flecken over posterior pole of 1 disc diameter (DD) in the right eye (OD) and 2 DD in the left eye (OS) associated with multiple cotton wool spots along the superior vascular arcades in both eyes (OU). Superficial nerve fiber layer hemorrhages along the superior vascular arcade in OD and over posterior pole in OS were also detected [Figures 1 (a) and (b)]. As per the diagnostic criteria laid by Agarwal et al., [1] Purtscher's-like retinopathy was established in this case. Fundus fluorescein angiogram [Figures 2(a) and (b)] showed symmetrically enlarged foveal avascular zone (FAZ) in OU corresponding to central retinal whitening in colored fundus photograph. In addition, this test also showed areas of hypo-fluorescence due to poor capillary filling corresponding to cotton wool spots along the vascular arcades. The margins of central ischemic zone had tortuous and dilated small retinal vessels with leakage or in other words pruning of vessels suggestive of necrotic

inflammation [Figure 2 (a) and (b) arrow mark]. In addition, there was blocked hypo-fluorescence in areas corresponding to intra-retinal hemorrhages in OU. The OCT evaluation based on light interferometry [Figures 3 (a) and (b)] (Stratus OCT Carl Zeiss Meditec, Inc., Dublin, CA) in OU showed abnormal retinal thickening with increased hyper-reflectivity in inner neurosensory layers of retina. Outer hyper-reflective layer, inner segment-outer segment junction, and foveal contour were within the normal limits in OU. The patient was started on high dose corticosteroid therapy (1.5 mg/Kg body weight) in tapering dose. Favorable response was seen in the next four weeks with the reduction in the whitish lesions with corresponding improvement in vision (OD 20/80 and OS 20/120) [Figure 1 (c) and (d)]. Visual acuity was maintained for 2 months, following which the patient was lost to follow up.

Discussion:

Purtscher's retinopathy was originally associated with severe head trauma.[2] However, it was also described in context to other disorders like acute pancreatitis, connective tissue disorders, long bone fractures, fat embolism, and renal failure. [3] The cases other than trauma with a similar clinical presentation are termed as Purtscher's-like retinopathy. [4] This paper reports a case of Purtscher's-like retinopathy associated with acute pancreatitis following alcohol abuse. The activation of the coagulation cascade (compliment activation) by the release of proteases from inflamed pancreas causes accumulation of leucocytes leading to the blockade of the intermediate-sized retinal vessels, which is considered as the pathophysiology of the condition. [5] However, the exact pathogenesis of the disease could not be established. Although the clinical diagnosis is very important, fundus fluorescein angiogram and OCT act as useful adjuncts in the diagnosis of this condition. The pathognomonic Purtscher's flecken is recognized in only 50% of the total cases reported [1]. The retinal non-perfusion surrounding the posterior pole in fundus fluorescein angiogram corresponding to Purtscher's

flecken helps in understanding the disease further and establishes the proposed hypothesis of ischemic vasculopathy [6] in the pathogenesis of the disease. In this case, OCT showed thickened inner layers with hyper-reflectivity that correlated well with the poor retinal perfusion of retinal inner neurosensory cell layers. [7] Although the role of corticosteroid in improving the visual outcome has been stated in the previous studies, [8], [9] there is no proper consensus regarding the steroid management owing to the sparse global reports. Therefore, it can be said that Purtscher's-like retinopathy is very much underreported, and to the best of our knowledge, this is the first case emanating from this region.

Table-1

- (1) *An associated contributing illness such as acute pancreatitis, long bone fracture, orthopaedic surgery, chest compression or crush injury*
- (2) *Multiple areas of polygonal retinal whitening between the retinal arterioles and venules (Purtscher flecken) and/or superficial cotton wool spots in one or both eyes*
 - a) *typically restricted to the posterior pole*
 - b) *accompanied by minimal, if any, retinal haemorrhage*
 - c) *no visible emboli in the large retinal vessels*
 - d) *no direct ocular trauma*

References

1. Agrawal A, McKibbin M. Purtscher's retinopathy: epidemiology, clinical features and outcome. Br J Ophthalmol. 2007 Nov;91(11):1456-9.
2. Purtscher O. Noch unbekannte befunde nach schadeltrauma. Ber Dtsch Ophthalmol Ges 1910;36:294-301.
3. Miguel AI, Henriques F, Azevedo LF, Loureiro AJ, Maberley DA. Systematic review of Purtscher's and Purtscher-like retinopathies. Eye (London). 2013 Jan;27(1):1-13.
4. Wu C, Dai R, Dong F, Wang Q. Purtscher-like retinopathy in systemic lupus erythematosus. Am J Ophthalmology 2014 Dec;158(6):1335-1341.
5. Mayer C, Khoramnia R. Purtscher-like retinopathy caused by acute pancreatitis. Lancet. 2011 Nov 5;378(9803):1653.
6. Papadaki M, Lefebvre P, Janssens S, Daguzan M, Postelmans L, Caspers L, Willermain F. Bilateral retinal ischemic vasculopathy in a pregnant patient. Retinal Cases Brief Rep. 2015 Spring;9(2):185-9.
7. Coady PA, Cunningham ET Jr, Vora RA, McDonald HR, Johnson RN, Jumper JM, Fu AD, Haug SJ, Williams SL, Lujan BJ. Spectral domain optical coherence tomography findings in eyes with acute ischaemic retinal whitening. Br J Ophthalmology. 2015 May;99(5):586-592.
8. Wang AG, Yen MY, Liu JH. Pathogenesis and neuroprotective treatment in Purtscher's retinopathy. Jpn J Ophthalmology 1988;42:318-22.
9. Atabay C, Kansu T, Nurlu G. Late visual recovery after intravenous methyl prednisolone treatment of Purtscher's retinopathy. Ann Ophthalmology 1993;25:330-3.